

Adverse Reactions to Voriconazole

Aileen E. Boyd,¹ Simon Modi,¹ Susan J. Howard,² Caroline B. Moore,² Brian G. Keevil,³ and David W. Denning^{2,4,5}

¹Department of Infectious Diseases and Tropical Medicine, North Manchester General Hospital, ²Antifungal Testing Laboratory, Hope Hospital, ³Department of Clinical Biochemistry and ⁴Education and Research Centre, Wythenshawe Hospital, and ⁵University of Manchester, Manchester, United Kingdom

(See the editorial commentary by Drusano on pages 1245–6)

Voriconazole is a new antifungal agent effective in the treatment of invasive aspergillosis. Interpatient variation in plasma concentrations is considerable—more than 100-fold. We describe 3 patients with diverse manifestations of toxicity (e.g., hallucinations, hypoglycemia, electrolyte disturbance, and pneumonitis) possibly attributable to high voriconazole concentrations. Measurement of plasma concentrations could be helpful in optimizing voriconazole dosages.

Herbrecht and colleagues [1] have recently reported improved response and survival rates for patients with invasive aspergillosis who received therapy with voriconazole (Vfend; Pfizer), compared with patients who received standard amphotericin B therapy. Given the generally dismal outcome of invasive aspergillosis, this is excellent news. They also report fewer adverse effects in the voriconazole arm. Our experience in Manchester, through participating in clinical trials and the compassionate release program, was that some adverse events were noted in association with high drug concentrations. Of 16 patients receiving voriconazole for acute or chronic invasive fungal infections between 1993 and 2001 for whom voriconazole trough concentrations in blood were measured, 3 patients had significant toxicity, all with high plasma concentrations. Patients 1 and 3 had serious adverse effects, which were reported to the US Food and Drug Administration, as required, but without voriconazole concentration data. In phase 2 studies that used 2 loading doses of 6 mg/kg followed by 3 mg/kg every 12 h, we found a >100-fold variation in plasma concentrations [2].

Case reports. Patient 1, a 51-year-old-man with a history

of moderate depression and diet-controlled diabetes mellitus but otherwise healthy, developed invasive orbital and sinus aspergillosis caused by *Aspergillus fumigatus* [2]. Prior itraconazole therapy was stopped, as it was ineffective. On day 1 of intravenous voriconazole treatment, the patient's electrolyte levels and renal and hepatic function test values were normal, except for an alkaline phosphatase level of 141 IU/L (normal range, 36–126 IU/L). A randomly measured glucose level was 6.3 mmol/L, and the result of a hemoglobin A1C test was normal. His blood count was normal, apart from a mean corpuscular volume of 106 fL and relative lymphopenia (lymphocyte percentage, 10.3% of a total WBC count of 5100×10^6 cells/L). The patient noted a temporary “drunken feeling” after infusion of voriconazole (2 loading doses of 360 mg [i.e., 6 mg/kg], then 180 mg [i.e., 3 mg/kg] every 12 h). On day 5 of voriconazole therapy, he was found to be confused and hypoglycemia was noted. He was taking no medication other than diclofenac (50 mg t.i.d.), occasional codeine/paracetamol tablets, and temezepam (10 mg) and dothiepin (100 mg) at night, all for days or weeks previously. Voriconazole therapy was stopped, and plasma was obtained for determination of the voriconazole concentration before and after administration of the last dose.

The next day, the patient developed low-grade fever, cough, and respiratory failure, and a chest radiograph showed fluffy infiltrates consistent with adult respiratory distress syndrome (figure 1); he experienced additional episodes of hypoglycemia that required frequent boluses of dextrose. The alkaline phosphatase level was 174 IU/L, electrolyte levels were normal, the urea level was 7.7 mmol/L (normal range, 3.2–7.1 mmol/L), the creatine kinase level was 249 IU/L (normal range, <170 IU/L), and the lactate dehydrogenase level was 686 IU/L (normal range, <620 IU/L). The patient required intubation and artificial ventilation. Findings of a transthoracic echocardiogram were normal and showed good left ventricular function. Results of blood and respiratory-specimen cultures and retrospective serologic tests for viral and atypical pathogens were negative. The patient's preexisting lymphopenia worsened (lymphocyte count, 220×10^6 cells/L with a total WBC count of 7300×10^6 cells/L). His T cell subsets were normally distributed, but his total CD4 cell percentage was only 36% (CD4 cell count, 79×10^6 cells/L). Thereafter, still requiring ventilation, the patient developed hepatosplenomegaly, but liver-function test values were almost normal, and the prothrombin time was 1 s greater than the control time.

A liver biopsy performed after 1 month of artificial venti-

Received 24 November 2003; accepted 11 May 2004; electronically published 23 September 2004.

Reprints or correspondence: Dr. D. W. Denning, Education and Research Centre, Wythenshawe Hospital, Southmoor Rd., Manchester M23 9LT, UK (ddenning@man.ac.uk).

Clinical Infectious Diseases 2004;39:1241–4

© 2004 by the Infectious Diseases Society of America. All rights reserved.
1058-4838/2004/3908-0022\$15.00

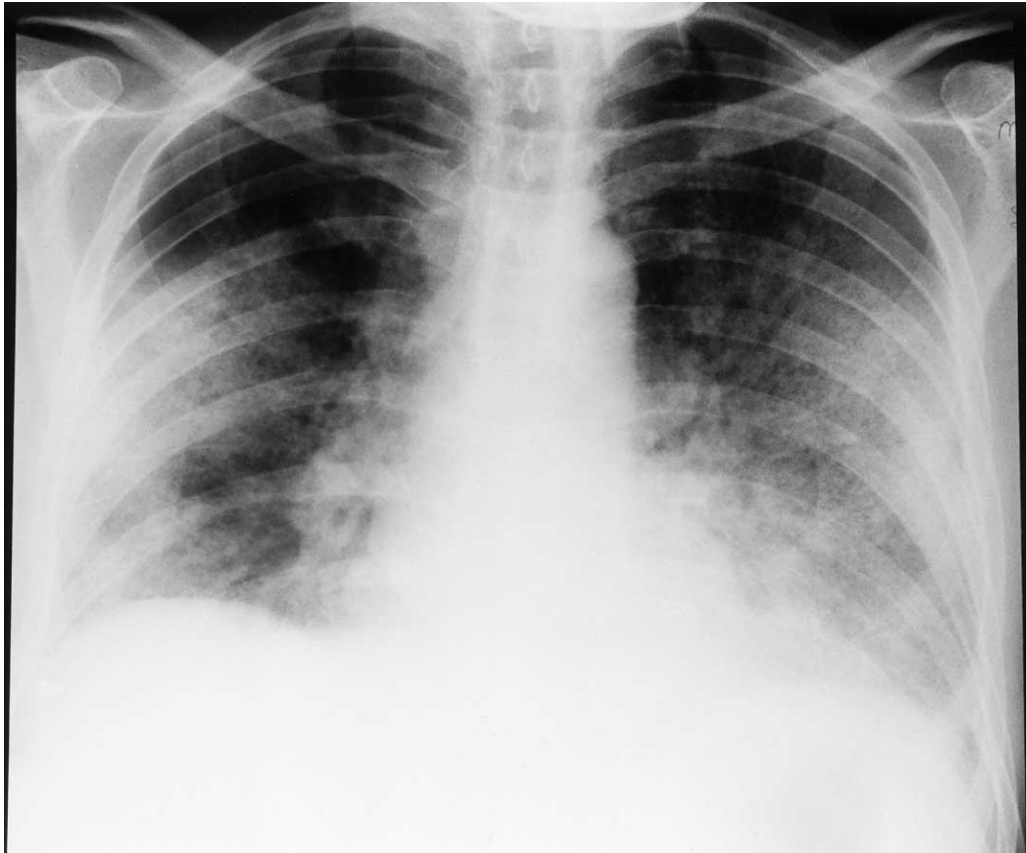


Figure 1. Radiograph of the chest of patient 1, who had orbital and sinus aspergillosis, showing bilateral fluffy infiltrates that occurred in association with confusion and hypoglycemia on day 6 after commencement of voriconazole therapy.

lation revealed cirrhosis, although there had been no stigmata of chronic liver disease. The patient died of intraperitoneal bleeding after the biopsy. The cause of the cirrhosis was initially unclear, although his general practitioner later described a history of concealed alcohol abuse. His trough voriconazole level on day 5 of voriconazole therapy was elevated, at 9.7 $\mu\text{g}/\text{mL}$, and 2 h after the start of his last infusion, the level was 13.9 $\mu\text{g}/\text{mL}$ (both measured for Pfizer using high-performance liquid chromatography). It is thought his underlying liver dysfunction may have impaired the metabolism of voriconazole, leading to very high voriconazole concentrations.

Patient 2, a 76-year-old man, a former paratrooper with long-standing steroid-responsive pulmonary fibrosis, developed invasive pulmonary *Aspergillus niger* infection. He had consumed alcohol in large quantities in the army but not since his marriage >40 years ago. Three days after commencing intravenous voriconazole therapy (loading doses of 6 mg/kg, then 4 mg/kg every 12 h), he became confused and 2 days later was hallucinating. Concomitant medication was maintenance therapy with prednisolone and frusemide. His trough voriconazole level on day 7 was high (8.96 $\mu\text{g}/\text{mL}$). There were no new clinical

or metabolic abnormalities to suggest any other cause for his symptoms. The patient had mild, persistent ankle edema and an elevated jugular venous pressure. His blood urea level was slightly elevated, with normal creatinine and electrolyte levels; his albumin level was 29 g/L. His alkaline phosphatase level was elevated (197 IU/L), and his alanine aminotransferase level was 81 IU/L (normal range, 21–72 IU/L). The voriconazole dose was reduced by 20%, and, within 24 h, his confusion improved. Subsequently, the trough voriconazole concentration remained high; it was 9.87 $\mu\text{g}/\text{mL}$ on day 10 and 9.44 $\mu\text{g}/\text{mL}$ on day 13, but thereafter fell to <8.0 $\mu\text{g}/\text{mL}$, with a further dose reduction and a switch to the oral formulation. On day 17, intravenous voriconazole was changed to the oral formulation, but the patient remained in the hospital for another 2 months with other medical problems. Voriconazole therapy was discontinued at week 12, in accordance with the trial protocol, and was replaced with itraconazole; a CT scan of the chest performed at this time showed a partial response.

Patient 3, a 77-year-old man who had numerous exacerbations of chronic obstructive pulmonary disease requiring frequent courses of oral steroids, as well as pulmonary *Pseudo-*

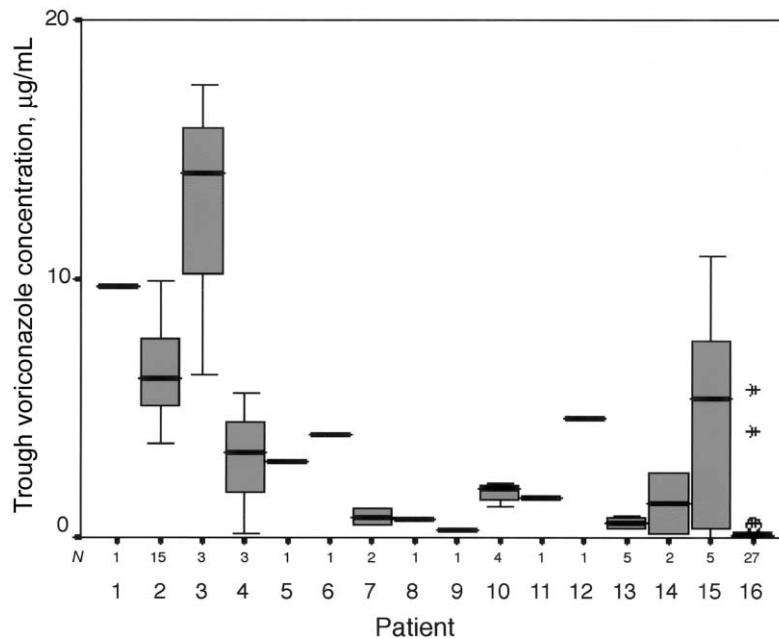


Figure 2. Box-plot of trough voriconazole levels (measured by bioassay and confirmed by high performance liquid chromatography and/or liquid chromatography–tandem mass spectrometry in most patients) in the 16 patients in the series. The 3 patients with significant adverse events who are described in the text are shown as patients 1, 2, and 3. *Thick bar*, median level; *box*, interquartile range; *whiskers*, minimum and maximum levels after exclusion of outliers and extreme values; *open circles*, outliers (values that lie 1.5–3 box lengths from the upper and lower edges of the box); *asterisks*, extreme values (those that lie >3 box lengths from the edges of the box). *N* values indicate the number of trough concentrations measured.

monas infections, developed acute invasive pulmonary *Aspergillus fumigatus* infection. He was almost a teetotaler, drinking alcohol perhaps twice per year. His infection failed to respond to itraconazole therapy, and he was treated with intravenous voriconazole (loading doses of 6 mg/kg, then 3 mg/kg every 12 h). On day 13 of voriconazole therapy, he became unresponsive (Glasgow Coma Scale score, 11/15) and hypotensive (blood pressure, 76/50 mm Hg). Electrolyte levels were deranged (sodium level, 118 mmol/L; and potassium level, 7.2 mmol/L), but creatinine, glucose, and liver-function test values were normal. The patient developed right bundle branch block. Blood and urinary osmolalities (250 mmol/kg [normal range, 275–295 mmol/kg] and 329 mmol/kg, respectively) were suggestive of adrenal failure, although a plasma cortisol level determined during the patient’s collapse was slightly elevated (572 nmol/L) and therefore inconclusive. Although the patient had received prolonged, intermittent steroid therapy, it was thought adrenal insufficiency alone could not account for the episode, because prednisolone therapy had been reduced slowly over a 10-week period and had been discontinued 3 weeks prior to the cardiac event. In the week prior to and on the day of the event, the patient was receiving salmeterol and beclomethasone (250 µg) via inhaler; frusemide (20 mg); amiloride, enoxaparin, etridonate, fluoxetine, prochlorperazine; and zolpidem at night. His trough voriconazole concentration on day 13 of therapy

was exceptionally high (17.5 µg/mL). He recovered during the following 5 days; a randomly measured voriconazole concentration determined on day 18 was 1.4 µg/mL.

Results. In figure 2 are depicted the trough voriconazole concentrations for all 16 patients for whom this information was determined. Trough concentrations varied substantially over time in some patients. For example, patient 4 (an alcohol abuser) was receiving carbamazepine when voriconazole therapy was started, and had an initial trough voriconazole concentration of 0.15 µg/mL, which rose to 3.3 and 5.6 µg/mL with voriconazole dose escalation and discontinuation of carbamazepine. Patient 15, a child with severe burns and multiple medical problems who was receiving phenobarbitone, had initial trough voriconazole concentrations of 0.32 µg/mL, which rose progressively, over 3 days, to 10.9 µg/mL while the patient was receiving 6 mg/kg of voriconazole twice daily, just prior to death from multiorgan failure. Some inpatient trough voriconazole concentrations results from the precise sampling time, the dose, the route of administration, and changes in the concomitant medication. Variation between patients was also substantial—several patients had trough concentrations of <0.5 µg/mL. Cutaneous photosensitivity reactions [4] were seen in patients with any plasma voriconazole concentration (data not shown). Many other patients were treated with voriconazole in our unit, and no other patients in our unit developed major

toxicity, as reported here, but not all patients had trough voriconazole concentrations measured. Because the time of the peak voriconazole concentration may vary between patients, especially if some are treated with the oral formulation, this information is less useful than trough concentrations in assessing drug exposure. A bioassay was used for measurement, which has considerable intrinsic variability, so elevated concentrations were confirmed by high performance liquid chromatography and/or liquid chromatography–tandem mass spectrometry [3, 5].

Discussion. Elevated voriconazole levels may be caused by hepatic dysfunction, genetic polymorphism of the isoenzyme CYP 2C19, or drugs that inhibit this enzyme. A CYP 2C19 polymorphism that leads to elevated plasma concentrations is found in ~3% of white Europeans and in 15%–20% of Asians [6]. Older patients tend to have higher voriconazole concentrations [7]. Two of the 3 patients described here were >70 years of age, and there was no obvious explanation for their high plasma voriconazole concentrations. In contrast, the children both received doses of >3 mg/kg, one to achieve detectable concentrations of voriconazole and the other to avoid an anticipated interaction with phenobarbitone.

Our previous report on the 116 patients with invasive aspergillosis treated with voriconazole included some information on voriconazole concentrations [2]. Most of the 517 samples that were collected and analyzable were intentionally collected throughout the dosing interval for determination of population pharmacokinetics, which precluded simple determinations of exposure or any assessment of concentrations and adverse events. Further analyses of the whole clinical study data set by staff at Pfizer, who attempted to determine the relationship between voriconazole plasma concentrations and abnormal liver-function test values, indicated that the risk of developing elevated liver-function test values increased by 7%–17% for every 1 $\mu\text{g}/\text{mL}$ increase in the random voriconazole concentration [8]. As no threshold was found, the investigators argued that therapeutic drug monitoring of voriconazole concentrations is not any more helpful in predicting abnormal liver-function test values than is measuring liver function directly.

We believe that voriconazole is the most effective drug currently available for the treatment of invasive aspergillosis. It should be used in place of amphotericin B if there are no contraindications to its use. We are concerned that some patients receiving intravenous voriconazole may develop adverse effects (e.g., hypoglycemia, electrolyte disturbance, and, possibly, confusion and pneumonitis) without any remarkable abnormal alterations in liver-function test values, as illustrated by the cases we describe. It may be that these adverse events are concentration related, although the heterogeneity of the

clinical manifestations makes this difficult to prove or disprove. Few randomly measured concentrations exceeded 6 $\mu\text{g}/\text{mL}$ in patients receiving oral voriconazole therapy [2], and it may be that the “first-pass” effect partially protects against accumulation and any risk of concentration-related toxicity. Babies and small children frequently have subtherapeutic concentrations and may require dose escalation to 5 to >10 mg/kg twice daily (authors’ unpublished data; Paul Verweij, personal communication). Caution is required in the use of larger doses, because plasma concentrations increase disproportionately, relative to dose increases. We therefore believe that a case can be made for therapeutic drug monitoring of patients receiving voriconazole.

Acknowledgments

We are indebted to Pfizer for providing voriconazole for the patients.

Financial support. The analysis of concentrations was funded through United Kingdom National Health Service research and development income streams.

Conflict of interest. D.W.D. has received grant support from Vicuron, Fujisawa, Merck, Pfizer, F2G, OrthoBiotech, Basilea, Wellcome Trust, the Fungal Research Trust, and the National Institute of Allergy and Infectious Diseases, both in the United States and the European Union; is a consultant for Merck, Fujisawa, Vicuron, AstraZeneca, Aventis, Basilea, Sigma Tau, Schering-Plough, and Indevus; has served on the speakers’ bureaus of Gilead, Merck, Fujisawa, and Janssen; and is a founder of and shareholder in F2G. All other authors: No conflict.

References

1. Herbrecht R, Denning DW, Patterson TF, et al. Randomized comparison of voriconazole and amphotericin B in primary therapy of invasive aspergillosis. *N Engl J Med* **2002**; 347:408–15.
2. Denning DW, Ribaud P, Milpied N, et al. The efficacy and safety of voriconazole in the treatment of acute invasive aspergillosis. *Clin Infect Dis* **2002**; 34:563–71.
3. Perea S, Pennick GJ, Modak A, et al. Comparison of high-performance liquid chromatographic and microbiological methods for determination of voriconazole levels in plasma. *Antimicrob Agents Chemother* **2000**; 44:1209–13.
4. Denning DW, Griffiths CEM. Muco-cutaneous retinoid-effects and facial erythema related to the novel triazole antifungal agent voriconazole. *J Exp Dermatol* **2001**; 26:648–53.
5. Keevil B, Newman S, Lockhart S, Howard SJ, Moore CB, Denning DW. Validation of an assay for voriconazole in serum samples using liquid chromatography–tandem mass spectrometry. *Therap Drug Monit* (in press).
6. Balian JD, Sukhova N, Harris JW, et al. The hydroxylation of omeprazole correlates with S-mephenytoin metabolism: a population study. *Clin Pharmacol Ther* **1995**; 57:662–9.
7. US Food and Drug Administration Antiviral Drugs Advisory Committee. Briefing document for voriconazole (oral and intravenous formulations). 4 October 2001. Available at: <http://www.fda.gov/ohrms/dockets/ac/01/briefing/3792b2.htm>. Accessed 7 May 2003.
8. Lutsar I, Hodges MR, Tomaszewski K, Troke PF, Wood ND. Safety of voriconazole and dose individualization. *Clin Infect Dis* **2003**; 36: 1087–8.